


Cat Anatomy and Physiology

4-H CAT PROJECT • UNIT 3 • EM4289E



WASHINGTON STATE UNIVERSITY
EXTENSION

4-H Youth Development Program 

ACKNOWLEDGEMENTS:

Our thanks to the 4-H leaders who contributed to the first edition: John and Sandy Edminster, Thurston County, and Mary Smith and Sue Hall, King County. Also to Roy J. Hostetler, DVM, former Extension Veterinarian.

Revised 2008 by Michael A. Foss, DVM, Skamania County; Nancy Stewart, King County; and Jean Swift, Skagit County.

RESOURCES:

The Anatomy of Domestic Animals, 5th Edition, Sisson and Grossman, WB Saunders Co., Philadelphia, 1975.

The Cornell Book of Cats, 2nd Edition, edited by Mordecai Siegal, Villard, New York, revised 1997.

Reader's Digest Book of the Cat, edited by Alice Philomena Rutherford, Readers Digest Association Ltd., Montreal, 1992.

The Royal Canin Cat Encyclopedia, Aniwa Publishing, Paris, 2001.

Dear Leaders and Parents:

This manual is primarily for 4-H members who have learned all the material in the previous two units and are at the senior level of 4-H (Grades 9-12). The focus of this unit is anatomy and physiology. Knowledge of the cat's body and how it functions is important to every cat owner and will prove useful in the pet's daily care. It will also be helpful when giving the veterinarian needed information and in the treatment of cat ailments and injuries.

CONTENTS

| | | |
|-----------|---|----|
| Chapter 1 | The Evolution of the Cat | 4 |
| Chapter 2 | The Five Senses..... | 9 |
| Chapter 3 | Musculo-Skeletal System..... | 12 |
| Chapter 4 | Respiratory and Circulatory Systems | 16 |
| Chapter 5 | Digestive and Urinary Systems | 18 |
| Chapter 6 | Reproductive System | 20 |
| Chapter 7 | Care of the Pregnant Cat and Kittens..... | 22 |
| Chapter 8 | Behavior | 25 |
| Chapter 9 | Vocabulary..... | 26 |
| | Worksheets | 30 |
| | Word Search and Crossword Puzzles..... | 36 |

CHAPTER 1

The Evolution of the Cat

Cat-like animals first came into existence about 65 million years ago. The oldest fossils showed a similarity to modern cats. These date back to 20 million years ago. Cats were the last in line to be domesticated. The oldest evidence of the domestication of cats is 4500 B.C. in Egypt.

Cats are an evolutionary marvel! Though humans are at the top of the evolutionary pyramid, being the most successful of all animals, the cat is not that far below. Cats represent the most supremely efficient muscular machines in their ability to jump, twist, and turn. The ratio of their strength to their size is far superior to humans.

As animals evolved, cats developed into the most efficient hunter of all. Their keen sense of sight, hearing, and smell make it easier to locate their prey. Strong legs to pursue and/or spring on their prey along with sharp claws and teeth to kill and tear apart the prey make cats very formidable. It has been documented that cats have a degree of reasoning ability. This moves them higher on the evolutionary ladder. This also makes cats more efficient hunters, especially since all but lions are generally lone hunters.

The Evolutionary Tree

I. Miacids:

Miacids existed in the Paleocene Age about 65 million years ago. They were the first ancestor of cats. Miacids fed primarily on flesh and blood of other vertebrates. They had short legs, long bodies, and were weasel- to wolf-sized. They lived in the forests. Like all carnivores (meat eating animals), they had carnassial teeth—large sharp molars and premolars in the upper and lower jaws that cut food in a scissoring action. They also had large sharp canine teeth for tearing flesh.

II. Aeluroidea and Arctoidea:

Miacids began to evolve into different families in the Eocene to Oligocene Ages, 53 to 34 million years ago. The two branches were known as Aeluroidea (or Feloidea) and Arctoidea (or

Canoidea). The Aeluroidea evolved in three groups, the Dinictis which gave rise to the felines, Hyaenids (hyenas), and Viverrids which became civets and mongooses. The Arctoidea evolved into four groups: Canids (dogs, wolves, foxes), Mustelids (weasels, mink, skunks, badgers), Procyonids (raccoons), and Ursinids (bears). In this chapter, we will only continue with the Dinictis line which eventually led to the domestic cat of today.

III. Dinictis

Dinictis came into being about 53 million years ago in the Eocene Age. With longer legs and tail and cat-like teeth for stabbing prey, Dinictis had become a better hunter. Dinictis developed in two different directions, Nimravidae (Paleofelids) and Felidae (Neofelids).

IV. Nimravidae and Felidae

Nimravidae was the first saber toothed cat that existed for approximately 30 million years. This large saber toothed cat (known as Eusmilus) was the size of a small puma, had claws that were not completely retractable, and walked on its pads. They were not as efficient as the Felidae and were more limited in intelligence, which eventually led to their dying out.

Felidae developed in two stages. The first stage was the Proailurus which developed in the Oligocene Age. This stage evolved into Pseudailurus, which arose in Europe and North America during the Miocene Age 23 million years ago.

V. Pseudailurus

Pseudailurus evolved into four groups. The earliest was the famed saber-toothed tiger—Smilodon. These creatures appeared 12 million years ago and survived for about 2 million years—into the Epoch of Man. It then died out.

Pseudailurus is the direct ancestor of the modern cat. It had a flattish skull, acute hearing, and walked almost flat-footed. The oldest fossils show a close similarity with the modern cat.

Starting in the Pliocene Age, 10 million years ago, the three modern branches began to evolve. Those branches are *Acynonyx*, *Panthera*, and *Felis*. *Acynonyx* are the cheetahs. They have an ossified hyoid bone that makes them unable to roar. They also have unretractable claws. Cheetahs are found only in the Old World.

Panthera are the large cats found in both the Old and New Worlds. These are the lions, tigers, leopards, and jaguars. They have a hyoid bone at the base of the tongue. It is partly cartilage, allowing it to move freely, enabling big cats to roar.

Felis is the largest of the cat families. This family of cats has an ossified hyoid bone and thus is unable to roar. Some of the better-known

members of *Felis catus* are cougar, lynx, ocelot, bobcat, margay, serval, and caracal. *Felis sylvestris* includes the Scottish wildcat, Spanish wildcat, and Indian desert wildcat. It is unlikely that these wildcats played a role in the development of the domestic cat. They are very reclusive and extremely fearful of humans. However, they do have the ability to crossbreed with domestic cats.

The first domestication of cats appears to be 8,000 years ago—compared to dogs which were domesticated 50,000 years ago. Overwhelming evidence points to ancient Egypt and the African wildcat (*Felis sylvestris libyca*) as being the origin of the domesticated cat.

WORKSHEET—CHAPTER 1

1. List the ages in order.
2. What two groups branched out from Miacids?
3. Dinictis had two branches. Which one became extinct?
4. From which sylvestrus genus did the domestic cat originate? What is its Latin name?
5. What is the common ancestor for the cat and the dog?
6. Why did the Nimravidae become extinct?
7. Catlike fossils were found that date back to 20 million years ago, but the oldest fossils most closely resembling the modern cat date back to _____ million years ago.
8. What is a hyoid bone?
9. What has happened to the hyoid bone in the cheetahs and the small cats? What are they unable to do because of this?
10. What made the feline the most efficient hunter of all?

FELINE EVOLUTION WORD SEARCH

P R O C Y O N I D S A N T A R T
 Z L A R H H O I M A E I O P T A
 S M I L O D O N I B L M O R B C
 E A I O N X N Y P E U R E O O C
 R R V A C O O R M R R E V A B I
 V G E O C E N E F T I V P I C T
 A A B S L I N C W O O I S L A S
 L Y K N I E D E P O D D L U T E
 A R C T O I D E A T E A Q R S M
 X I E F N O Q R N H A E K U L O
 S W I D P V B E T E S F R S S D
 C D Q O E R B V H D Y U E D N C
 O L I G O C E N E T L O T N O A
 T R E S C E A S R I Y I P A O A
 T A G X E J R T A G G A J A C C
 I E O N P C S O L E A E E Y A A
 S F O P A O D L R R M I N K R L
 H Q C N L U C E E F R O E M S Q
 O U I L E G S C D I N I C T I S
 R D W S O A R O H Y E N O C C P
 S L P Y C R Y J X N Y L I B A O
 P I V F E L I D A E L P M E A T
 D O C I N V U O C S R A U G A J
 S Y L V E S T R I S X R D L I W

Acynonyx
 Aeluriodea
 Arctoidea
 Bear
 Bobcats
 Canids
 Cat
 Catus

Cougar
 Dinictis
 Dogs
 Domestic Cat
 Eocene
 Felidae
 Fox
 Jaguars

Lion
 Lynx
 Margay
 Miacid
 Mink
 Miocene
 Neofid
 Nimrevidae

Ocelots
 Oligocene
 Paleocene
 Panthera
 Pliocene
 Proailurus
 Procyonids
 Pseudailurus

Raccoons
 Saber Toothed Tiger
 Scottish
 Serval
 Smilodon
 Sylvestris
 Tiger
 Tree
 Wild

CHAPTER 2

The Five Senses

Vision

Cats have exceptional eyesight. Particularly in the early evening and at night, they see better than humans. Most cats can see kinds of light, such as ultraviolet, that are invisible to humans. In the course of their development, the ability to see at night while hunting was favored over the ability to see colors during the day. As far as scientists have been able to tell, cats are more or less colorblind.

One phenomenon of cat vision is the tapetum lucidum, or “eyeshine”, the glowing of cat’s eyes in the dark. A layer of iridescent cells at the back of the eyeball reflects the light, which adds to the cat’s ability to see at night.

A cat’s eyes are complicated and delicate organs. Even small injuries can render a cat blind. The eyes appear as large, round globes or orbs, with a transparent covering known as the cornea. Around the cornea is a ring of white, shiny tissue called the sclera. The nictitating membrane, or third eyelid, is located in the lower part of the cat’s eye. This eyelid serves as protection for the eye. Cats have partial vision through the third eyelid, and often use it as protection when fighting or when traveling through dense underbrush. When the nictitating membrane is clearly visible, it is usually a sign that the cat does

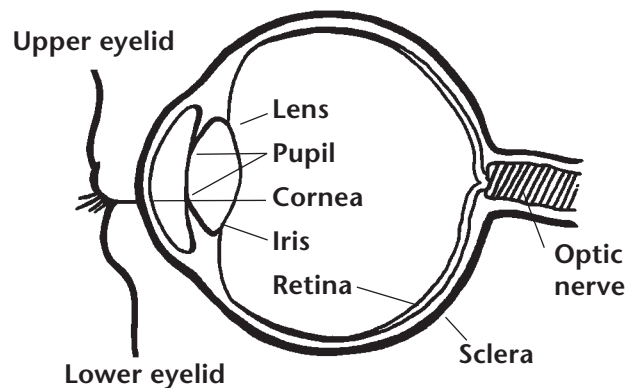


The cat’s pupil narrows in bright light and opens wide in dim light.

not feel well. It is not specific to any one area and means you should examine your cat closely for a problem.

In the center of the eye is the pupil. It is actually a hole, formed by the iris, which expands or contracts to let in the correct amount of light. When exposed to bright light, the pupils contract into linear slits. In darkness they open very wide to allow in as much light as possible.

Behind the pupil is the lens, which focuses images on the back of the eyeball. It is composed of strong, crystal-like fibrous tissue. Light rays passing through the lens are bent to rest on a very sensitive area on the back of the eye, the retina. It is richly lined with nerves. The nerves in the retina receive light and change it into nerve impulses or signals. Impulses are transmitted to the brain by way of the optic nerve. The brain interprets these impulses and lets the cat “see.”



Cross Section of Eye

Hearing

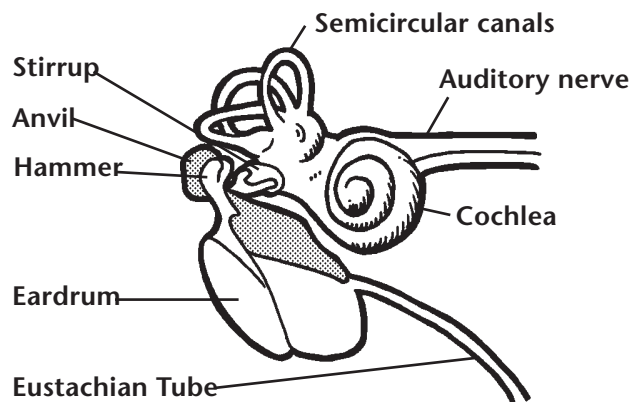
Cats are exceedingly sensitive to sound; their range of hearing extends well above and below the range of human hearing. It is probable that the cat has a keener sense of hearing than most dogs, since it depends more upon sight and hearing than smell when hunting.

Cats, like all four-legged animals, have cupped

ears which serve as receptors and conductors of sound. When listening, the cat will move its head this way and that, turning its ears in the direction of the sound. The sound travels down through the outer ear canal, which is fitted with small knobs or protuberances. The outer ear tapers and narrows near the cat's skull, then turns downward and inward, ending in a delicate membrane known as the eardrum. All of the hearing faculties are protected within the skull.

Beyond the eardrum are three small, delicate bones: the hammer, anvil, and stirrup. The names describe the shapes of the bones that function to transmit sound waves into a section of the inner ear known as the cochlea. The cochlea, a snail shaped canal, contains the auditory nerve which changes sound waves into nerve impulses (nerve signals) and relays sound messages to the brain. Near the cochlea are three horseshoe-shaped tubes known as the semicircular canals. They contain fluid and fine hairs called cilia that function to maintain the cat's excellent sense of balance.

Connecting the middle ear to the throat is the Eustachian tube. Its main purpose is to equalize pressures. Without this safety device, the eardrum would be ruptured when subjected to great pressure. When pressure is exerted on its ears, a cat swallows and sticks out its tongue.



Inside of Cat's Ear

Sense of Smell

The cat's olfactory nerves, those concerned with its sense of smell, are not as sensitive as those of some other animals, but are quite adequate. Cats can scent people, animals, and other objects at a considerable distance, but they do not rely on this sense while hunting as much as other animals

do. Fastidious about odors, they dislike many of the same smells that humans do. They will try to cover up disagreeable smells.

Most cats have a particular fondness for catnip, a member of the mint family. It is believed they are excited by the smell. Some authorities believe that the odor of catnip stimulates the cat sexually. Catnip is harmless and you can give your cat as much of the "feline snuff" as it wants. It may enjoy nibbling on the leaves of a catnip plant, or playing with a catnip-stuffed toy. Some cats are not affected by catnip, some become just quietly excited, while others roll, purr, and growl in ecstasies of delight. The occasional cat may become disagreeable.

Sense of Taste

The cat's tongue is long and flat, with almost parallel sides. It tapers slightly in front and somewhat more in the back of the mouth. The upper surface of the tongue is covered with rasp-like papillae which enable the cat to scrape every piece of meat off a bone or to lick its coat clean. The tongue is covered with taste buds, particularly at the tip and at the back of the throat. These taste buds react to chemical stimuli to produce sensations of acidity, sweetness, bitterness, and saltiness.

Sense of Touch (Hair and Skin)

The least important sense in a cat is the sense of touch. Both the skin and the hair play a role in that sense.

First of all, the hair or fur serves as insulation against heat and cold. Hair also protects the cat against insect bites, stings, thorns, and other dangers and annoyances. The cat raises its hair, particularly the hair along its neck and spine, as a protective device when frightened or threatened. With its hackles raised, the cat assumes a wary and defiant position. Back arched, tail hairs bristling, muscles tensed, it turns itself broadside. In this attitude, the cat appears larger and more ferocious to its attacker.

Cats shed their hair according to climatic conditions and their state of health. Hair is shed naturally year round, especially in the spring and fall. Excessive shedding is a warning signal of possible disease, poor diet, parasites, or overheating. Therefore, it is important to pay

attention to the condition of your cat's hair.

The cat's skin is made up of an outer layer, the epidermis, and an inner layer, the dermis. The epidermis consists of four sub-layers, with the innermost providing for the regeneration of skin cells.

Skin functions to protect the body from the external environment. Skin protects against injuries and prevents excess loss of water, electrolytes, and large molecules. Skin is the first layer of defense in the immune system as it physically blocks bacteria, viruses, fungus, and other pathogenic (disease causing) organisms.

While the cat's skin is somewhat waterproof, it is not impermeable. That is, certain oils and medicines can be absorbed through the skin.

This should be kept in mind when you use any insecticides or medications on a cat's skin. A toxic substance may prove fatal if absorbed through the skin.

The skin has many glands. Sweat glands are located only on the foot pads. Sweating is only a small portion of thermoregulation (keeping the body at a correct operating temperature). The cat cools itself primarily by panting. Cats also have glands in their skin that are connected with the hair follicles, known as sebaceous glands. They secrete an oily substance known as sebum that solidifies when exposed to the air. It coats the hairs, thus protecting the fur and making it glossy. In a healthy state, the cat's skin is always elastic and pliable, with the ability to regenerate at a rapid pace.

CHAPTER 3

Musculo-Skeletal System

The cat's skeleton is not so different from the human skeleton. The cat has more bones—230 as opposed to 206—but many are identical to those in the human being. Cats have 13 ribs; humans have 12. Cats do have clavicles (collar bones) but unlike humans, they are not attached to other bones. The outside of a bone, the cortex, is composed of minerals and protein and gives the bone its rigidity. Inside the bone is the marrow cavity that produces red blood cells.

The cat's muscles are tough and well-coordinated and help to make the cat an agile hunter. Basically, the cat's muscles are designed for walking, running, leaping, and twisting. Because of their unusual musculature, cats are extremely nimble. The cat's muscular control and skeletal flexibility enable it to right its body during a fall with incredible speed—a trick that is unique to cats.

Skeleton

The body of the skeleton consists of five major areas; the spinal column, skull, ribs, forelegs, and hind legs. The spinal column is composed of five regions, the cervical, thoracic, lumbar, sacral, and caudal regions. The first region holds the cervical or neck vertebrae. The first two cervical vertebrae have special names, the atlas and the axis. There are a total of seven cervical vertebrae. The thoracic (chest) region has 13 vertebrae and each vertebra is associated with a pair of ribs. The lumbar area has seven vertebrae and ends at the pelvis. The pelvis contains three sacral vertebrae that are all fused together. It usually takes 18 to 23 caudal vertebrae to make the tail. The cat's spine is very flexible. It is probably the most flexible of all mammals. A cat can arch its back in a "U" shape.

There are 13 pairs of ribs. All are attached at the top to a thoracic vertebra. Most are attached at the bottom to the sternum or breastbone. Collectively, the spine, ribs, and sternum form the thorax that houses the heart and lungs. This rigid structure is needed to allow breathing to occur.

The skull is attached to the spinal column at the atlas. The skull actually consists of many bones

all fused into one functional unit. Inside the skull are air filled pockets called sinuses. The cat has a frontal sinus and a maxillary sinus. A major part of the skull, which holds the upper teeth, is called the maxilla, and the lower teeth are held by the mandible. The small bones that provide structure to the nose are called nasal bones.

As mentioned above, the skull holds the teeth. In the adult cat there are a total of 30 teeth. There are 12 incisors, four canines, 10 premolars (six on top, four on the bottom) and four molars. In the kitten there are 26 deciduous teeth. The numbers of incisors, canines, and premolars are the same but there are no molars in kittens.

The front or foreleg bones consist of the scapula or shoulder blade, humerus, radius, ulna, carpus or wrist bones, metacarpus, and phalanges or digits. The hind leg bones are the pelvis, femur, patella or kneecap, tibia, fibula, tarsus or hock, metatarsus, and phalanges or digits.

Joints

Joints are formed by the union of two or more bones. There are many joints within the cat's body. Joints are usually held together by connective tissue called ligaments and tendons. Ligaments are connective tissue that is attached to bone on both ends. Tendons are connective tissue that is attached to bone on one end and muscle on the other. The joints are cushioned by cartilage—a cushioning layer over the ends of the bones meeting at a joint. There are two types of joints. The hip and shoulder joints are ball and socket. They are able to move in a forward, backward, and sideways motion. The other joints are hinge type and are only able to flex and move forward and back. The major joints of the foreleg are the shoulder, the elbow, and carpus or wrist. The major joints of the hind leg are the hip, stifle or knee, and hock or ankle.

Locomotion

The cat's skeleton serves as a strong framework for the muscular system. This structural system allows for some very important actions such as

protection for vital organ and locomotion of the cat. The cat has several gaits, or patterns of locomotion. The most common are: the walk, a 4-beat gait (meaning each foot lands on the ground at a separate time); the trot, a 2-beat gait with contra-lateral (opposite side of body) front limb and rear leg striking the ground at the same time; and the run, a 3-beat gait. Some cats will pace instead of trot. This is a 2-beat gait where the foreleg and the rear leg on the same side of the body move forward at the same time.

Unfortunately, motor vehicle accidents kill or injure many cats each year. Most frequently broken bones are the bones of the forelegs and hind legs and the pelvis.

Muscular System

The cat, like all mammals, has three kinds of muscles. There are striated muscles, cardiac muscles, and smooth muscles. Striated muscles make up the majority of muscles. Striated muscles are the ones involved in voluntary movement and are usually attached to bone. They allow the cat to walk, breathe, and look around. These muscles are the flesh of the body—the legs, back, chest, and head. Striated muscle gets its name from its appearance under the microscope as it has small stripes or striations.

Cardiac muscle is a specialized striated muscle. It is found only in the heart and contracts automatically. There is no conscious control of the heart.

Smooth muscle gets its name because under the microscope it does not have striations; it looks smooth! It is the muscle of organs. It is not under voluntary control. It is found in the wall of the digestive tract where it moves food from the stomach into the intestines and through the intestines without any conscious control. Smooth muscle is also in the walls of the urinary tract and reproductive tract. It is in the walls of arteries, bronchioles, and in the eye.

Skeletal Muscles of the Cat

Skeletal muscles function by crossing a joint and moving bone or cartilage. Each muscle has a specific action or job. The muscle either extends the joint (makes the angle of the joint larger) or flexes the joint (makes the angle of the joint smaller). There are hundreds of muscles within the cat. The following is a list of some of the major

muscles. Muscles are usually named for the areas of attachment. Often both origin (where the muscle began) and insertion (where the muscle ends) are included in the name and sometimes its function. Dorsal refers to the top part of the body and ventral refers to the bottom, or toward the ground.

Muscles of the Head and Neck

Temporal and Zygomaticoauricularis muscles pull the ears forward; Caudal Auricular muscles pull the ear back. Levator nasolabialis raises the upper lip and dilates the nostrils. Masseter closes the jaw. It is the muscle of mastication or chewing. Buccinator forms part of the cheek and aids in movement of food in the mouth. Brachiocephalicus originates on the head and neck and extends to the shoulder.

Muscles of the Dorsal Body

The Trapezius muscle raises the head and shoulder. Latissimus dorsi flexes the shoulder. Thoracolumbar fascia serves as an anchor to a number of back and abdominal muscles.

Muscles of the Thorax, Abdomen, and Tail

Intercostal muscles connect the ribs to one another. They aid in breathing. External abdominal oblique is a large superficial muscle that forms part of the abdominal wall. Rectus abdominis originates from the sternum and inserts on the pelvis. It makes a major ventral support for the abdomen. The Sarcocaudalis muscle manipulates the tail.

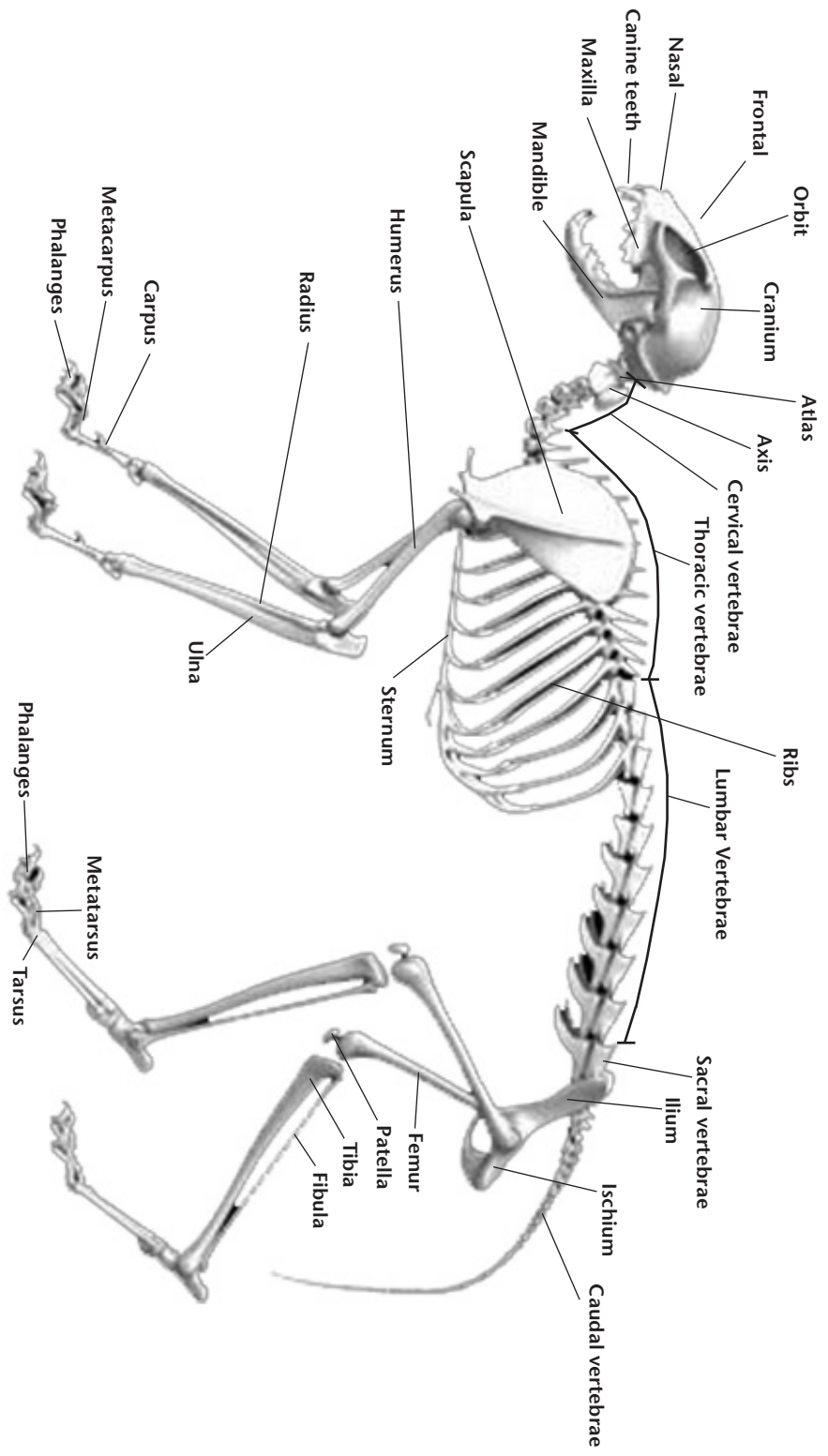
Muscles of the Forelimb

Brachiocephalicus helps to extend the shoulder. Infraspinatus supports the shoulder joint. Deltoidus flexes the shoulder. Brachialis flexes the elbow. Triceps extends the elbow. Flexor carpi radialis, Extensor carpi ulnaris, and Flexor carpi ulnaris together control the carpus. Digital flexors and digital extensors control the phalanges (toes).

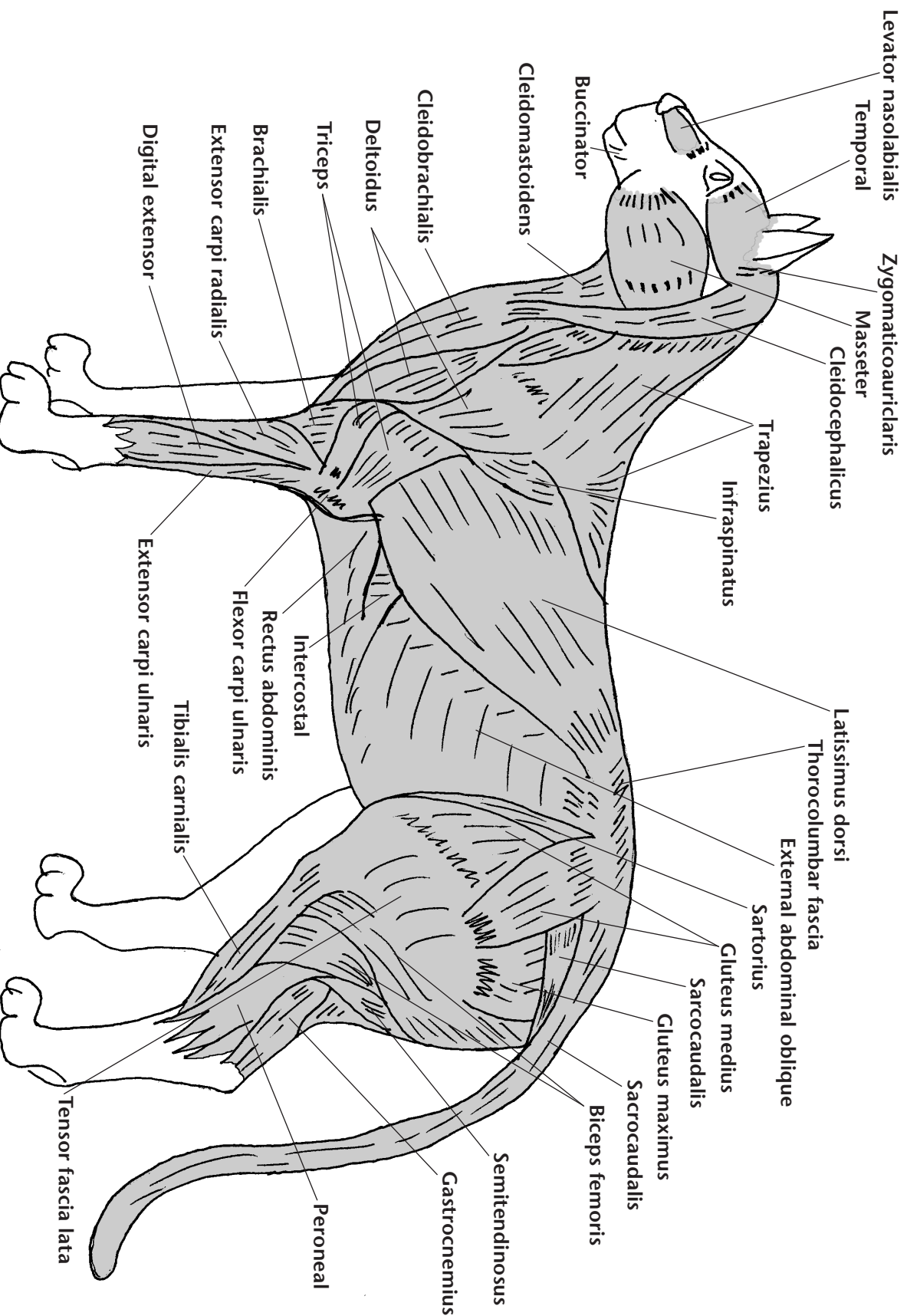
Muscles of the Pelvic Limb

Sartorius muscles flex the hip and extend the stifle. Medial gluteal is the major muscle of the rump. It flexes the hip. Biceps femoris flexes the stifle. Tensor fascia lata helps flex the hip. Semitendinosus is the rear most muscle of the thigh. It extends the hip. Gastrocnemius flexes the stifle and extends the hock. Common and lateral digital extensors extend the toes.

SKELETON OF THE CAT



MAJOR MUSCLES OF THE CAT



CHAPTER 4

Respiratory and Circulatory Systems

Respiratory System

The respiratory system functions primarily to transfer oxygen from the air to the blood and to remove carbon dioxide from the blood and carry it out of the body into the air. Oxygen is vital to the body's maintenance. Carbon dioxide is a waste product of the maintenance process. The cat breathes in air through its nose and mouth. The nose and mouth join to form the pharynx. The trachea is a tube that extends from the pharynx to the lungs. The epiglottis covers the trachea when swallowing occurs to prevent food and water from entering the lungs. At the lungs the trachea branches into smaller tubes called bronchi or bronchial tubes. The bronchi divide into smaller and smaller bronchioles until they become dead end sacs called alveoli. It is in the alveoli where the actual exchange of oxygen and carbon dioxide occur.

All mammals have a muscle that separates the respiratory system (lungs) from the rest of the internal organs. This muscle is called the diaphragm. The diaphragm works with the muscles between the ribs called "intercostals" to produce inspiration (or breathing in). Exhalation (or breathing out) is muscle relaxation, causing the air to move out of the lungs and body.

When the diaphragm is torn or ruptured, usually as a result of being hit by an automobile, a diaphragmatic hernia is created. This allows abdominal organs into the chest, collapses the lungs, and creates a life threatening condition.

The respiratory system also aids in regulating the body temperature.

Circulatory System

The circulatory system consists of the heart, blood, blood vessels, lymphatic system, and spleen. The circulatory system functions are to deliver oxygen and nutrients to the cells of the body and to remove waste products.

Heart

The heart is a marvelously specialized muscle. The heart has four chambers with four valves and contracts in a specific squeezing pattern. This squeezing action pumps blood through the heart out to the lungs and body. At a resting pulse of 120 beats per minute, a cat's heart will beat 63 million beats in a year! It is the closure of the heart valves that gives the "lub dub" heart sounds.

Blood Vessels

The blood vessels include arteries, veins, and capillaries. Arteries are the vessels that carry blood away from the heart, and veins carry blood back to the heart. The largest artery is called the aorta. It carries freshly oxygenated blood to the body. Capillaries are tiny vessels where the arteries end and the veins begin. Capillaries are only large enough for one blood cell to pass through at a time. It is in the capillaries where nutrients, oxygen, and waste products are exchanged with individual body cells. Most live healthy cells in the body are in contact with a capillary. The largest veins are called the cranial and caudal vena cava. They carry the oxygen-depleted blood back to the heart. The heart then pumps that blood to the lungs via the pulmonary artery. Following oxygenation in the lungs, the blood is carried back to the heart through the pulmonary vein, and the cycle begins again.

Blood

Blood is composed of cells suspended in a special fluid called plasma. The majority of the cells in the blood are red blood cells. Red blood cells contain hemoglobin, which functions by carrying oxygen and carbon dioxide. It is hemoglobin that gives blood its characteristic red color.

Blood also carries white blood cells. The job of the white blood cells is to fight infection or invasion by anything foreign. The blood also includes platelets. Platelets are small cells that help in blood clotting.

Lymphatic System

The lymphatic system helps to return to the heart the fluid that has leaked out of blood vessels. Lymph vessels are the tubes that carry lymph fluid, and lymph nodes are the filters for lymph fluid. Lymph nodes also make some white blood cells. Lymph fluid is not pumped by the heart. Instead, it moves by muscular and intestinal activity.

Spleen

The spleen is a long narrow purplish organ situated behind the stomach. It functions to filter blood, destroy old red blood cells, store red blood cells, and produce certain kinds of white blood cells.

CHAPTER 5

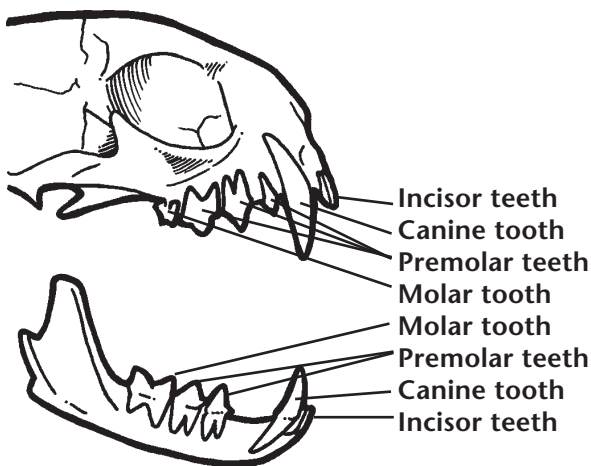
Digestive and Urinary Systems

The Digestive System

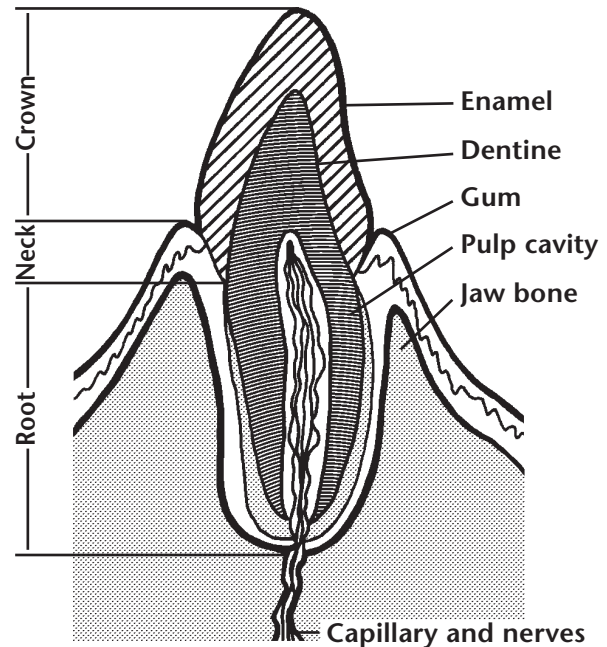
The cat's digestive system is comprised of the alimentary canal and accessory glands. The alimentary canal consists of the lips, mouth, teeth, tongue, esophagus, stomach, small intestine, large intestine, and anus. The accessory glands are the liver, pancreas, and the salivary glands. All the organs work to process the food a cat eats. The intestines work to extract and absorb the nutrients and eliminate the wastes.

Mouth: The cat's mouth is the doorway to the digestive system—the opening through which it takes in food. Its lips hold in food and retain saliva. The tongue is rough and covered with hook-like appendages. A cat uses its tongue to lap up liquids and to scrape food off bones.

Teeth: Cats have 30 permanent teeth. A first set of 26 teeth, the milk teeth, fall out when the cat is between five and seven months old and are quickly replaced by the permanent teeth. Its permanent teeth are made up of 12 incisors, four canines, 10 premolars, and four molars. The ability to hold and tear food is essential to a cat, which is why a cat's canines are so well developed and its molars are so sharp. The crown is the part of the tooth visible above the gums. Below the gums lies the root. At least half of each canine tooth grows below the gum line. Enamel covers



Teeth



Cross Section of the Tooth

the crown and neck of each tooth. Inside each tooth is the pulp, which houses the nerves and blood vessels. Cats have thin enamel that leads to cavities. The teeth also have shallow roots that lead to easy tooth loss if tartar builds up and gingivitis becomes severe.

Salivary Glands: The salivary glands are located behind the jaw. Their function is to moisten food as an aid in swallowing and digesting.

Pharynx: The pharynx is a tube shared by the digestive and respiratory systems. Food enters the pharynx from the mouth through the action of the tongue and leaves through the esophagus. During the act of swallowing the epiglottis closes over the trachea to prevent food from entering it.

Esophagus: The esophagus is a strong elastic tube that carries food from the pharynx to the stomach.

Stomach: The cat's stomach, a sac-like organ with elastic walls, has a comparatively large capacity for food storage. In the stomach, some of the early stages of digestion take place; acid liquids

help to break down proteins. At the bottom of the stomach is the pylorus, a muscular valve that moves the food into the small intestine.

Small Intestine: The duodenum is the first section of the small intestine. The small intestine secretes digestive enzymes. The enzymes break down proteins and carbohydrates. Bile and pancreatic juices enter the intestine here. Together, these substances break down or digest food. Once these substances have broken down the food, it can be absorbed into the body. What is left over is passed on to the large intestine.

Large Intestine: The large intestine's purpose is to absorb moisture out of the waste products and then pass the waste products out of the body. The rectum is the last segment of the large intestine. It is very short and is located entirely within the pelvis. The anus is the muscular closure at the very end of the large intestine.

Liver: The liver is the largest organ in the cat's body. It is situated just behind the diaphragm and mostly on the right side of the body. Its functions are to filter blood, destroy toxins within the blood, produce many proteins, manufacture bile,

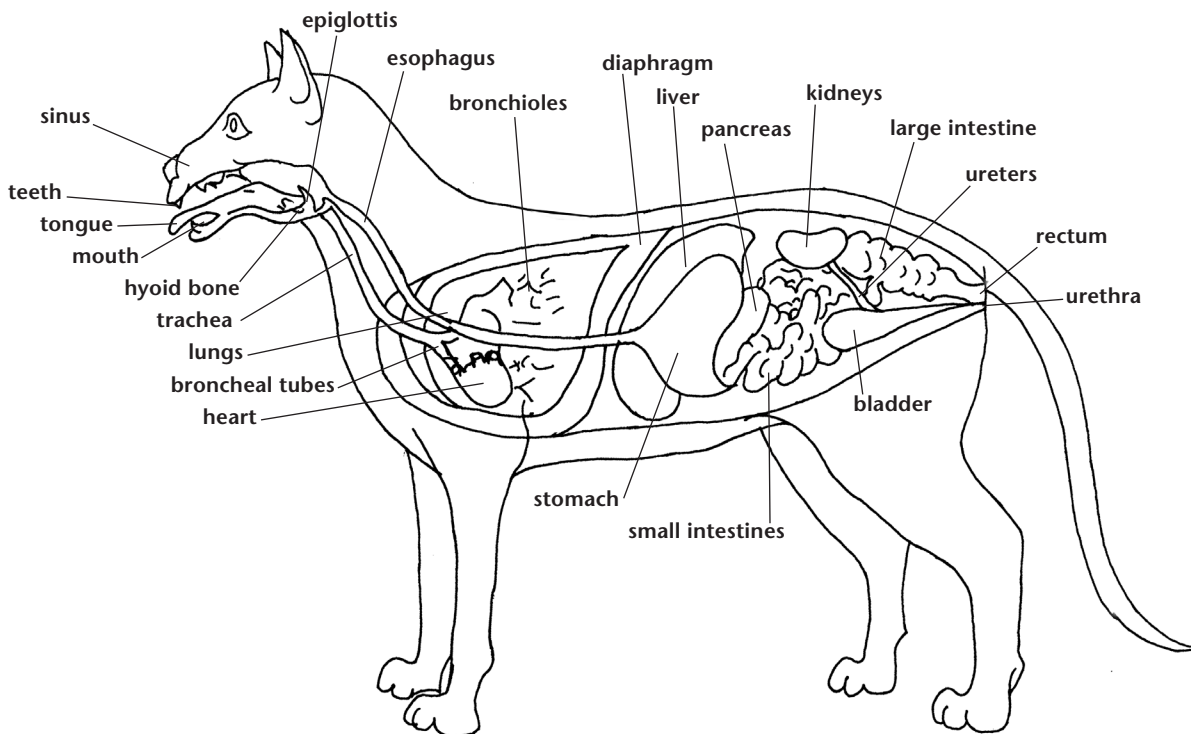
and store sugar in the form of glycogen. Bile is produced to aid in the digestion of fats. Between meals, it is stored in the gall bladder and moves through the bile duct to the small intestine after a meal.

Pancreas: The pancreas is located near the stomach and is attached to the small intestine. The pancreas makes digestive juices called enzymes. In addition, the pancreas contains the Islets of Langerhans. These small glands produce insulin that is essential in utilization of blood sugar. Diabetes is a condition that occurs when there is a lack of insulin.

The Urinary System

The important organs of the cat's urinary system are the kidneys, ureters, bladder, and urethra. The kidneys are located on either side of the body in the lumbar region (between ribs and pelvis). Blood is filtered through the kidneys and the liquid waste product is called urine. Urine is passed through the ureters to the bladder where it is stored. The urine is then discharged through the urethra, a tube connecting the bladder to the exterior of the body.

INTERNAL SYSTEMS OF THE CAT



CHAPTER 6

Reproductive System

Cats are fertile animals. A queen, or intact female cat, may produce two or three litters of kittens a year, which is one reason for the large number of stray, unwanted kittens. Female cats go into heat during which time they are interested in mating and can conceive (get pregnant) if they do mate. A female can mate with more than one male. Periods of heat last a few days. Rolling, stretching, rubbing, crying, and yowling characterize a female cat in heat. If the cat does not mate and conceive, the cycle will be repeated in a few weeks. It is possible to prevent a female cat from becoming pregnant. You can keep her in the house, isolated from any tomcats (unneutered males) during her heat, or you can have her spayed (ovariohysterectomy). Spaying is a surgical procedure which involves removal of the female reproductive organs. The operation is usually performed at age six to seven months, although it can be done successfully later on, after a cat has had kittens. After being spayed, a cat is no longer interested in mating and she is unable to conceive.

Many cat owners choose to have their pets neutered or spayed. This is done to prevent the birth of unwanted kittens. It also makes male cats more suitable house pets. Neutering a male cat involves surgical removal of the testicles. A neutered male no longer shows interest in mating. A tomcat tends to roam a lot, get into many fights, and mark his territory. Territory is marked by spraying urine on walls, inside and outside of your house. The odor of the urine is unpleasant and enduring. Tomcats seldom live to an old age. A neutered male tends to stay home, fight less, and live much longer than toms.

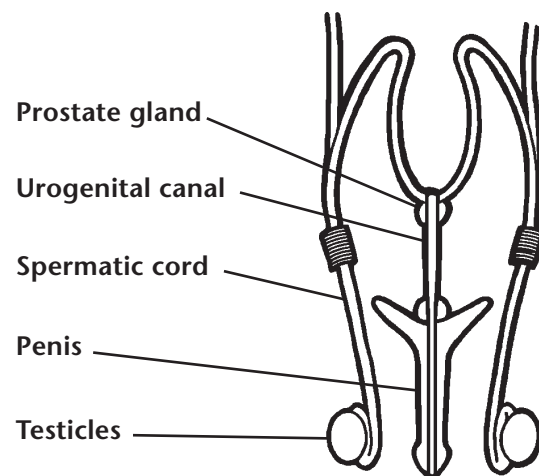
A common myth against spaying and neutering is that the pet will get obese. This can be successfully prevented by not overfeeding the pet.

Male Reproductive Organs

The tomcat's (male cat) organs of reproduction are the penis, testicles, and prostate gland. A male cat has two testicles that are suspended in a sac-like structure, the scrotum, outside of its body.

The testicles produce and store sperm, which is the seed that fertilizes the eggs produced by the female. Testosterone, a hormone that is essential to the male's sexual development and activity, is also produced by the testicles. The prostate gland produces seminal fluid, which transports the sperm.

When two cats mate, the male mounts the female and inserts his penis into her vagina. This is called copulation. The act of copulation ends after the male ejaculates (squirts) seminal fluid into the female's vagina. The sperm in the seminal fluid then swim up through the vagina into the uterus and finally into the oviduct. It is in the oviduct where the sperm actually fertilize the eggs.

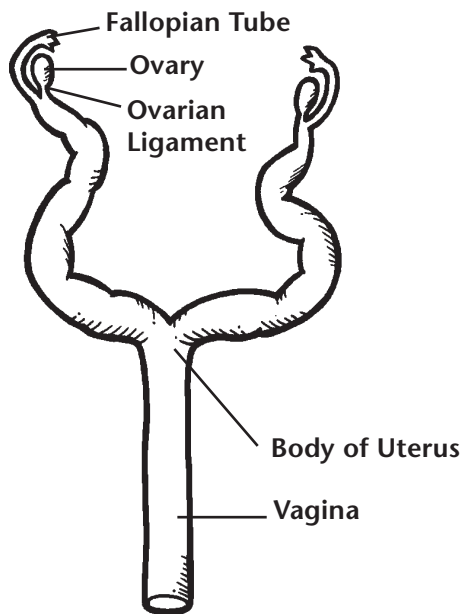


Male Reproductive Organs

Female Reproductive Organs

The female cat's reproductive system consists of the vulva, vagina, cervix, uterus, oviducts, and ovaries. The vulva is the external opening of the reproductive tract. The lips of the vulva are located just below the anus. The vagina is a tube just inside the vulva. It is where the male's penis will be during copulation as well as the passageway for kittens being born. The vagina is also the location of the end of the urethra. The

cervix is next. (It is the opening between the uterus and vagina. During pregnancy it serves as a seal or barrier between the sterile uterus and the outside world. It relaxes at birth and allows the kittens to enter the vagina. The uterus is a tubular organ that is shaped like a "Y", the body being the bottom part of the Y and the horns the top part. The uterus extends from the pelvis to the kidneys. It consists of a body and two horns. It is in the horns of the uterus that kitten embryos are implanted and develop. The oviduct is a tiny tube that connects the uterus to the ovaries. The oviduct is the actual site where fertilization occurs. The ovaries are a peanut-sized organ located near the kidneys.



Female Reproductive Organs

Ovaries and the Estrous Cycle

The ovaries are where ova or eggs are produced. The ovaries control the estrous cycle. The estrous cycle is the recurrent pattern of sexual receptivity followed by periods of time without sexual receptivity in the female. The most distinct period is estrus, or heat, and this is the time of sexual receptivity or breeding. The hormones estrogen and progesterone are made in the ovary during different stages of the estrous cycle.

The estrous cycle begins with the development of several follicles. A follicle is a small fluid sac that will contain an egg. Each follicle will grow and produce estrogen. Estrogen is the hormone which is responsible for the "in heat" or estrus behaviors of the female. Ovulation is the rupture of the follicle and release of the egg into the oviduct. Cats are induced ovulators, meaning ovulation occurs as the result of mating.

After ovulation, the follicle changes to form a corpora leuta (CL). The CL produces progesterone, which is a hormone needed to maintain pregnancy. If the cat does not have kittens the CL will keep her "out of heat." When the CL quits producing progesterone, follicles will begin to grow and another estrus cycle will begin.

The cat is known as a seasonally polyestrous animal. This means she will have many estrous cycles only during certain times of the year. It is photoperiod, or length of day, which controls the estrous cycle. Therefore, cats usually will not come into heat during the winter but will wait until springtime.

CHAPTER 7

Care of the Pregnant Cat and Kittens

Nothing contributes more toward a healthy litter of kittens than good care during the mother's pregnancy. If she is in good health at the time of mating, her pregnancy should pose no problem. Be sure she is up to date on her vaccines before breeding. Early in her pregnancy, make sure she is eating a balanced diet, treat any skin conditions, eliminate parasites, and make sure that she is in good health.

The average gestation period—the time from mating to the birth of kittens—is 61 to 63 days. It is not unusual for a cat to deliver her kittens a few days before or after this period. However, if the gestation period lasts longer than 65 days and if you are certain of the breeding date, consult a veterinarian. A pregnant cat or a cat with kittens is referred to as a queen. In a group situation, especially a feral cat situation, the queen is the dominant cat.

False Pregnancy

A false pregnancy is a condition in which the female displays physical and emotional signs of pregnancy, but is not carrying kittens. The cat's breasts swell and produce milk. Her abdomen is distended. She eats more and gains weight, and continually works at preparing a nest for the kittens she expects but is not to have. The symptoms usually appear after the cat has gone out of heat and may persist for several months. You will have to wait a month or so before you can determine whether or not the cat is pregnant. As a true pregnancy progresses, the kittens, which feel like lumps in the cat's abdomen, grow. Although she will manifest most other signs of pregnancy, a cat with a false pregnancy will not have any apparent lumps.

If your cat has a false pregnancy, you will have to cater to her peculiarities. She may exhibit constant meowing, working on a nest, or mothering odd objects. False pregnancies can recur. While the cat can mate and bear kittens, there is no way of knowing if and when a false pregnancy might happen again. Spaying will eliminate the condition.

Prenatal Care

The cat should be given a health examination early in her pregnancy. Examine her for fleas, lice, and ticks, and keep her free from other pests. Have a veterinarian examine a stool specimen for signs of worms or other internal parasites. Remember, roundworms and hookworms can be transmitted to the fetuses. Deworming is best done before pregnancy or during the first two weeks of pregnancy. If you find signs of worms or suspect worms, consult with your veterinarian. He/she will know what products are safe to use in the pregnant female. Kittens can normally be dewormed at the time of their first vaccinations usually about 6 weeks of age. Sometimes it is necessary to deworm kittens at an earlier age; do this only after consulting with your veterinarian.

The pregnant cat is hungry most of the time, especially in the later stages. Feed her well without overfeeding her. After the first month, two or three meals a day will suffice. The simplest way to feed her is to give her kitten food. It will contain the needed vitamins, minerals, protein, and energy she needs. Most importantly, it will be balanced. Avoid simply giving supplements without examining overall balance of the diet.

As her pregnancy continues to progress, the cat will become more and more inactive and will lie about. Leave her alone as this is perfectly normal. Around the eighth week of pregnancy, milk usually appears in the cat's mammary glands. The glands will swell and may become hard. The cat may show signs of discomfort, especially constant licking. If her mammary glands become dry and cracked, apply hot packs and small amounts of olive oil.

As the time for her delivery draws near, the cat will become very restless, wandering around and scratching at her bed. Keep an eye on her as she may decide to have her kittens in some secluded place, such as a cellar, garage, or even in an old barrel, box, drawer, or other such out-of-the-way place. The cat may lose her appetite from 12 to 24 hours before the kittens are due.

Preparing for the Arrival of Kittens

You can make some preparations for the big event. If your cat is long-haired, trim away the hair around her breasts. This will help the kittens find the nipples. Also trim the hair around the anus and vagina.

Birth

In a normal birth, all kittens will be born within two to eight hours after labor begins. If a cat continues to labor more than eight hours, something is wrong. Call your veterinarian for instructions. Also consult him/her if more than three hours elapse between kittens. Queening is another term for birthing.

The Placenta

Each kitten is born encased in a transparent sac or membrane (a grayish, bulky mass) through which the kitten is visible. The membrane is attached by a cord to the placenta, or afterbirth, and should come out immediately after the kitten. The placenta, the lifeline from the mother cat, is the means by which the kitten feeds while in the uterus.

Do not become alarmed if your cat eats the placenta; it is normal. It may be her way of removing all traces of the birth, or perhaps it provides her with a temporary source of nourishment, since she will be unable to leave the newborn kittens for some time.

Try to keep count of the placentas as each one is expelled. A placenta should follow the birth of each kitten. Sometimes a placenta is retained when the cord between the fetal membrane and the placenta breaks. If the cat does not expel the placenta, it must be removed in another way. Grasp the broken cord with a clean towel and gently and slowly pull out the placenta. A retained placenta may interfere with the birth of the next kitten and, if retained after the last kitten is born, will decompose and cause infection.

As the Cat Continues Labor

Even after the first kitten is born, there is no assurance that the others will follow quickly. Remain near the cat and if more than three hours elapse between the arrival of one kitten and the next, call a veterinarian. Tell the veterinarian when the first kitten was born, whether it was a

normal or breech delivery, how long the cat has been in labor with the present kitten, and other pertinent information.

If all goes well, the kittens should be delivered and nursing within a few hours. The mother will stop laboring and panting shortly after delivering the kittens and will settle down to taking care of her family. The mother will sometimes become so involved with her kittens that she will refuse to eat. Some mothers have been known to go as long as 24 hours without eating. When she does want to eat she will let you know in unmistakable ways. Then feed her the canned kitten food she has been eating. Warming it may make it more appealing. Keep fresh water near her at all times.

Some Possible Obstetric Difficulties

Most cats have no difficulty in delivering kittens. Obstetric troubles are called dystocia. Dystocia may be caused by disease or malfunction of the reproductive system.

Breech Delivery: In a breech delivery, the kitten arrives hind feet first. Usually the head of a breech kitten is large and the cat has difficulty in expelling the kitten.

Caesarian section: When kittens cannot be born in a normal manner, they must be delivered through an incision in the cat's abdominal wall and uterus. The operation is called a Caesarian section.

The need for a Caesarian section can sometimes be anticipated early in pregnancy when the veterinarian determines either by X-rays or by feeling that the kittens are going to be too large to be delivered normally. Sometimes the veterinarian must perform a Caesarian to remove the remaining kittens after one or two kittens are born. A cat's uterine muscles may become overly tired, particularly if she has a long difficult labor, making her unable to expel the kittens. Call the veterinarian if your cat labors more than eight hours.

Postnatal Period

Eclampsia: Eclampsia is a serious condition that rarely happens to a cat. When it does occur, it is well into the nursing period. It is brought on by a depletion of the blood calcium. The symptoms include excessive panting, loss of appetite, a temperature above 103 degrees, a stilted walk, and convulsions, eventually followed by collapse

and coma. There is nothing you can do. Rush the cat to the veterinarian, where she can be quickly revived by the injection of calcium gluconate into her bloodstream.

The cat will have a discharge from her vagina for a week to ten days. This discharge should be red or dark red in color. If it is greenish, greenish-yellow, or white, there is something wrong. A placenta may have been retained despite your vigilance and serious infection may result. Such an infection may cause the cat's milk to dry up and eventually lead to her death and that of her kittens. When you see a green, greenish-yellow, or white discharge, CONTACT YOUR VETERINARIAN IMMEDIATELY!

Care of the Newborn Kittens

The mother and kittens should be left strictly alone for the first two or three days. Nursing kittens are very delicate, so avoid unnecessary handling. Caution children not to pick up the baby cats.

During the first 10 days of life, the physical activities of the newborn kittens are very limited. They cannot see or hear; their legs are too weak to support their bodies; and they must get around by crawling on their abdomens with a swimming motion. Baby cats will cry when they are hungry and sometimes stray from the warmth of their mother's body. Provide some barricade to prevent the kittens from getting too far from the mother.

Watch the kittens closely for the first week to make certain they are getting enough to eat. The mother's rear breasts contain the most milk and the most vigorous kittens will monopolize them. You can rotate the kittens on the rear breasts so that all get enough nourishment.

Excessive leanness, weakness, and constant crying are signs that a kitten is not getting enough milk. Such kittens quickly become dehydrated. To check for dehydration, pinch the skin at the back of the kitten's neck with your thumb and forefinger, then quickly release it. If the animal is dehydrated, the skin will not snap back to its former position but will remain pinched. If your mother cat does not have enough milk or dies

while nursing, you will have to bottle-feed the kittens.

Bottle-feeding: You should have little difficulty in getting the kittens to feed from a bottle or eyedropper. Use an eyedropper, baby doll bottle, or special baby animal bottle for the first few days, and later switch to a larger bottle. Newborn kittens need to be fed every 1 to 2 hours.

Two- or three-day-old kittens do not eat much at a feeding. An average newborn kitten consumes from about 5 to 25 drops at one feeding. Use the dehydration test to see if the kittens are getting enough of the formula. You should keep a supply of formula stocked in the refrigerator and warm any portion you feed to the kittens. If you use a commercial formula, follow the directions of the manufacturer. Clean and sterilize all utensils and bottles after each feeding. Here is a formula that has proved successful: ½ cup evaporated milk, ½ cup water, 1½ tablespoons light cream, and 2 drops water-soluble vitamins.

Weaning the Kittens: The mother will begin to wean the kittens somewhere around the fourth or fifth week. First she will reduce the number of feedings each day by spending more and more time away from them. Then she will begin to bring food to the kittens and teach them how to eat. When she begins to wean the kittens, take up feeding yourself. Remember to introduce new foods gradually and avoid overfeeding. High quality commercial kitten food is the best ration. Food should be at room temperature. When the kittens are eight weeks old, they should be totally weaned.

Remember to provide the weaned kittens with their own sleeping quarters, food and water pans, and a litterbox if one is not already available. The mother cat will take care of housebreaking her kittens. You should handle and groom the kittens from now on. A visit to the veterinarian for a distemper-rhino (FVCRP) shot and a general checkup is in order.

Remember, it is cruel, inhumane, and illegal to abandon kittens. If you are unable to care for or find homes for the kittens, take them to your local humane society.

CHAPTER 8

Behavior

Intelligence

The cat is an intelligent animal, capable of learning quickly and retaining what it has learned. It also appears to exercise a certain degree of reasoning in solving problems. For example, a cat will examine a building to find out if there is more than one exit from a mouse's lair. If satisfied that a mouse can escape from no other exit, a cat will sit for hours in front of a mouse hole, waiting for its unsuspecting dinner to appear.

Although it is not easy to teach cats to perform on command, they can learn tricks, but the process takes infinite patience. When its own welfare is involved, a cat is quick to learn. Otherwise, it is simply too aloof and independent to be brought under the same control as a dog.

Temperament

Cats' temperaments, or dispositions, vary greatly. On the whole, they are inclined to be more aloof and independent than dogs. Some of them are moody, aggressive, nervous, and quick to resent any hurt or neglect. On the other hand, many cats are docile and even-tempered. Most respond well to affection, gentle handling, and pampering.

Cats are creatures of habit and really don't care for much change. A change in attitude such as sudden aggression or going off by itself to hide can indicate a problem. In this case, the cat should be observed closely to determine if the problem is physiological or psychological. For example, a

cat urinating in an unusual place may indicate a bladder infection or the cat may be upset about some sort of change in its environment.

Anger

An angry cat assumes a classic pose. Ears laid back, and a switching tail are early signs of irritation. When really angered, it reacts rapidly by arching its back and stiffening its body. All hairs stand on end, and the cat snarls and spits. The cat may drop into a crouch, with its tail lashing from side to side. As it prepares to fight, the ears are pressed flat against the head, mouth partly open, fangs bared, forefeet firmly planted, claws extended.

Affection

In expressing affection, a cat is pure gentleness. It will arch its back, hold its tail stiff and straight, perk its ears, rub its head and muzzle against people and objects—purring its delight to the world. A cat may also show its affection by licking and touching and sniffing delicately with its nose.

Courage

Cats are very courageous animals, often attacking animals twice their size, especially when their young are threatened. They will chase away large dogs, kill large birds of prey, and sometimes get badly injured in the process of protecting their young or homes.

CHAPTER 9

Vocabulary, Worksheets, and Puzzles

VOCABULARY

- Alveoli:** Sacs enclosed by blood capillaries that allow gases to escape or be absorbed.
- Anvil:** One of three small bones in the middle ear that transmits sound waves to the cochlea.
- Aorta:** The main artery from the heart to the rest of the body; carries oxygenated blood.
- Arteries:** Blood vessels that take blood away from the heart.
- Atlas:** First vertebra of the spinal column, attached to the skull.
- Auditory nerve:** Relays sound messages to the brain.
- Axis:** Second vertebra of the spinal column just below the atlas.
- Bile:** Fluid made by the liver and stored in the gall bladder; secreted into the duodenum where it breaks down the fat.
- Bladder:** A sac that serves as a receptacle for liquids.
- Blood:** Fluid in the body that carries nourishment and oxygen to body cells and waste products away from them.
- Bronchi:** Larger tubes leading from the trachea and branching within the lungs.
- Bronchioles:** Small tubes branching from the bronchi that carry oxygen and carbon dioxide through the lungs.
- Cardiac muscle:** Specialized striated muscle found only in the heart.
- Caudal:** Tail vertebrae.
- Cervical:** Vertebrae of the neck.
- Cervix:** Opening to the uterus; connects vagina and uterus.
- Cochlea:** Snail-shaped canal that contains the auditory nerve.
- Copulation:** The mating act of a male and female.
- Cornea:** Transparent covering of the eye.
- Corpora lutea:** Ovarian follicles after the discharge of ova (eggs).
- Crown:** Visible part of the tooth.
- Delivery:** Passage of kittens from the uterus, through the birth canal, to the outside world.
- Dentine:** Inner part of the crown.
- Dermis:** Inner layer of skin.
- Dorsal:** Pertaining to the back.
- Duodenum:** First section of the small intestine where much digestion takes place.
- Dystocia:** Obstetrical or birthing problems.
- Eardrum:** Membrane in the ear that turns sounds into sound waves.
- Eclampsia:** Depletion of blood calcium; a serious condition that can occur during the nursing period.
- Enamel:** Hard, protective, outer covering of the tooth.
- Epidermis:** Outer layer of skin.
- Epiglottis:** Flap that covers trachea while swallowing to prevent food from entering it.
- Esophagus:** Strong, elastic tube connecting mouth and stomach.
- Estrogen:** A hormone made in the ovaries by follicles; hormone responsible for female's breeding behaviors.
- Estrous:** The cycle of the recurrent pattern of sexual receptivity followed by periods of time without sexual receptivity in the female.

Estrus: The period of time, during the estrous cycle, when the female is sexually receptive and allows breeding; another term for heat.

Eustachian tube: Connects ear and throat; equalizes pressure.

Extend: To open or make larger the angle of a joint.

False pregnancy: Cat shows all of the physical and mental signs of pregnancy without actually being pregnant.

Fertilization: Union of egg and sperm, necessary for egg to develop into a kitten.

Fetus: The unborn kitten developing in the uterus.

Flex: To close or make the angle of a joint smaller.

Follicle: A small cavity, sac or gland.

Gall bladder: A sac that stores bile.

Gestation: The time from mating to the birth of the kittens.

Hair (fur): Slender, threadlike outgrowths of an animal's skin.

Hair follicle: A small cavity from which a hair develops.

Hammer: One of three small bones in the middle ear that transmits sound to the cochlea.

Heat: Period during which female can mate and get pregnant; a time when she shows a strong interest in mating with male cats.

Hemoglobin: A complex protein that functions to transport oxygen and carbon dioxide.

Impermeable: Allows nothing to pass through.

Induced ovulation: Ovulation occurs as a result of mating.

Iris: Colored part of the eye, around the pupil, that regulates pupil size.

Joint: The union of two or more bones.

Kidney: Filtering organ of the urinary system.

Large intestine: Last part of the digestive system.

Lens: Crystal-like fibrous tissue behind the pupil that bends light rays to focus on the retina.

Ligament: Connective tissue attached to bones at both ends.

Liver: Largest organ in the body; makes bile and urea, helps regulate sugar utilization.

Lumbar: Vertebrae of the lower back.

Lungs: Respiratory organs located in chest that function to transfer oxygen into the blood and remove carbon dioxide from the blood.

Lymph nodes: Islands of tissue in the lymphatic system that filter the lymphatic fluid and produce some white blood cells.

Mandible: Lower jaw.

Maxilla: Upper jaw.

Mouth: Doorway to digestive system.

Neuter: Surgical removal of the male's testicles.

Nictitating membrane: Third eyelid; strong, protective membrane.

Olfactory nerve: Carries odor impulses to the brain.

Optic nerve: Carries images to the brain.

Ova: Eggs produced by the ovaries.

Ovarian follicle: The ovum (egg) and its surrounding cells.

Ovaries: The bodies in the female cat's reproductive system which form the eggs or ova.

Oviduct: The tube connecting the ovary with the uterus; fertilization of eggs occurs here.

Oxygenate: To enrich with oxygen.

Pancreas: Manufactures insulin that functions in sugar utilization; also manufactures many enzymes that aid in the breakdown of nutrients.

Patella: Knee cap.

Pathogenic: Disease causing.

Penis: Male reproductive organ which is used in copulation.

Pharynx: Tube shared by digestive and respiratory systems; located from back of mouth to trachea and esophagus.

Physiological: Pertaining to the functions and processes of living organisms.

Placenta: Lifeline from the mother to the kitten; means by which the kitten feeds while in uterus.

Plasma: The fluid portion of blood.

Pregnancy: Having a fetus or fetuses developing in the uterus.

Progesterone: Hormone made by the corpora lutea within the ovaries that helps maintain pregnancy.

Prostate gland: Produces the seminal fluid.

Psychological: Pertaining to the mind or mental phenomena.

Pulmonary artery: Carries oxygen-depleted blood from the heart to the lungs.

Pulmonary vein: Carries oxygenated blood from the lungs to the heart.

Pupil: Hole in the center of the eye through which light rays pass.

Pylorus: Muscular valve at the bottom of the stomach; entrance to the small intestine.

Red blood cells: The blood cells that carry hemoglobin.

Regenerate: Regrow.

Retina: Receives and transmits images to the brain.

Root: Part of the tooth located below the gum line; holds tooth in place.

Sacral: Vertebrae at the pelvis that are fused together.

Salivary gland: Located behind jaw; moistens food to aid in swallowing and digesting.

Sclera: White, shiny tissue around the cornea.

Scrotum: Saclike structure which holds the testicles.

Sebum: Oily substance secreted from skin glands that coats cat's hairs.

Semicircular canals: Contain fluid; essential to cat's balance.

Seminal fluid: Fluid produced by prostate gland that transports the sperm; during copulation, seminal fluid is ejaculated through the male's penis into the female's vagina.

Sinus: Air-filled pocket within the skull.

Small intestine: Tube into which food passes from the stomach; process of digestion is completed; nutrients are absorbed into the blood stream.

Smooth muscle: The muscle of organs; it is not controlled voluntarily and it does not have microscopic stripes.

Spay: Surgical removal of the female's internal reproductive organs.

Sperm: Seed produced by the male, stored in the testicles, that fertilize the ova (eggs).

Spleen: An organ that stores red blood cells, destroys old red blood cells and produces some white blood cells.

Sternum: Breastbone.

Stirrup: One of three small bones in the middle ear that transmits sound to the cochlea.

Striated muscle: The muscle of voluntary movement; microscopically, it has stripes.

Tapetum lucidum: Specialized reflective layer beneath the retina; makes cats' eyes shine in the dark.

Tendon: Connective tissue attached to bone on one end and muscle on the other.

Testicles: Manufacture and store sperm; manufacture testosterone.

Testosterone: Hormone produced by the testicles, essential to male's sexual development and activity.

Thermoregulation: Keeping the body at a correct operating temperature.

Thoracic: Vertebrae of the chest.

Trachea: Tube that connects the throat or pharynx with the lungs.

Ureters: Tubes that connect kidneys and bladder.

Urethra: Tube that connects the urinary bladder to the exterior of the body.

Urinary bladder: A sac that serves as a receptacle and storage place for urine.

Uterus: Female internal reproductive organ where fertilized eggs develop into kittens.

Vagina: Connects outer and inner female reproductive systems; passageway for male cat's penis during copulation; canal through which kittens pass as they are being born.

Veins: Blood vessels that return blood to the heart.

Vena cava: Large veins that carry blood to the heart.

Ventral: Toward the belly surface.

Vertebra: Spinal column bone (plural: vertebrae).

Vulva: External part of female reproductive organs.

White blood cells: Blood cells responsible for defending the body against disease-causing agents.

WORKSHEET—CHAPTER TWO

1. What are the five senses? Which two senses are the most acute in a cat?
2. The lens is made up of _____, _____, _____ tissue . What happens to light rays when they pass through the lens? _____
3. What does the retina do? _____
4. The cochlea is _____-shaped, and contains the _____ which changes _____ into _____ and relays _____ to the _____.
5. The _____ contain _____ and _____ and function to maintain _____.
6. The Eustachian tube goes from the _____ to the _____. What is its purpose? _____
7. What is the purpose of the olfactory nerve? _____
8. What are the purposes of papillae? _____, _____
9. Where are sweat glands located? _____ How does a cat cool itself? _____
10. A cat's skin is somewhat _____ but not _____. It is _____ and _____ with the ability to _____.

WORKSHEET—CHAPTER THREE

1. What are the five major areas of the skeleton? _____, _____, _____, _____, _____.
2. What are the five areas of the spinal column and how many vertebrae are in each area?

3. The thorax is made up of the _____, _____ and _____.
It houses the _____ and _____.
4. The skull is a single bone. True or False? _____ Why? _____

5. A kitten has _____ teeth. An adult cat has _____ teeth. What are they and how many of each are there? _____
Which teeth do kittens lack? _____
6. Joints are formed by _____ and are held together by _____ tissues called _____ which are attached to _____ on both ends and _____ which are attached to _____ on one end and _____ on the other.
7. What are the three types of muscle? _____, _____. And _____, _____. Which are voluntary and which are involuntary? _____

8. A muscle either _____ (makes a joint angle larger) or _____ (makes a joint angle smaller). The point of muscle attachment is called _____ where the muscle began and _____ where the muscle ends. _____ refers to the top of the body and _____ refers to the bottom or toward the ground.

WORKSHEET—CHAPTER FOUR

1. The primary function of the respiratory system is to transfer _____ from _____ to the _____ and remove _____ from the _____ and carry it out of the _____ to the _____.
2. Air travels through the _____, _____ and _____ before entering the _____ where the exchange of _____ and _____ occurs.
3. The _____ is the muscle that separates the _____ from the rest of the body. It works with other muscles to produce _____ (breathing in) and _____ (breathing out).
4. In addition to breathing, the respiratory system also does what? _____
5. The circulatory system delivers _____ and _____ to the cells of the body and removes _____.
6. The heart has _____ chambers. The three types of blood vessels are _____ and _____. _____ carry blood from the heart, _____ carry blood to the heart and _____ are where _____ and _____ are exchanged for _____ from the individual cells.
7. The components of blood are _____, _____, _____, and _____. The red color of blood comes from _____, the component that carries _____ and _____.
8. The _____ is an organ that _____ blood, _____ old blood cells, _____ red blood cells, and _____ some white blood cells.

WORKSHEET—CHAPTER FIVE

1. What do you call the tube that is shared by the digestive and the respiratory systems? _____
What prevents food from entering the respiratory system? _____
2. Early digestion begins in the _____. At the bottom, the _____
Moves the food into the _____.
3. The glands of the digestive system are _____, _____
and _____. The _____ are located _____
and their function is to _____.
4. The largest organ in the cat's body is the _____. It produces _____ that aids
in digesting _____. That product is stored in the _____ and
travels through the _____ to the _____ after a
meal. Other functions of this organ include _____ blood, destroy _____
and store _____ in the form of _____.
5. The other gland of the digestive system is the _____. It produces digestive
juices called _____ and contains small glands called _____
that produce _____. This product is necessary in utilizing _____
_____. Lack of this product causes _____.
6. The first section of the small intestine is the _____. _____
_____ secreted by the small intestine together with _____ and
_____ digest the food so it can be _____ into the
body. That which is left over moves to the large intestine where _____
is removed and the remaining waste product is moved through the last section of the large
intestine called the _____ and out of the body.
7. Blood is filtered through the _____ where a liquid waste product called
_____ is produced. That product passes through the _____,
is stored in the _____ and passes through the _____
to the outside of the body.

WORKSHEET—CHAPTER SIX

1. What is the technical term for spaying? _____
At what age can this be done? _____
2. Neutering a male cat is done by removing the _____. In addition to not producing kittens, a neutered male is less likely to _____, less likely to _____, less likely to _____ and may live longer.
3. Sperm fertilize the eggs in the _____. The fertilized eggs implant and develop in the _____ of the _____.
4. The three hormones involved in reproduction are _____, _____ and _____.
The male hormone, _____, is essential to a male cat's _____. One female hormone, _____, is responsible for the _____ or _____ cycle. The other, _____, is needed to maintain _____.
5. What is the difference between estrous and estrus? Estrous is _____
_____. Estrus is _____
_____.
6. A follicle is _____ that produces _____ and an _____. The follicle _____ to release the _____ into the _____. This process is called _____.

WORKSHEET—CHAPTER SEVEN

1. Prenatal care is important. Preferably prior to pregnancy, the female cat should be current on _____, should have a _____, and should be checked for _____. When the female is pregnant, it is recommended she be fed _____ because it contains _____.
2. When a kitten is born it is encased in a _____ attached by a cord to a _____. If a _____ is retained in the uterus, it can cause an _____. All kittens should be born within _____ hours. If the mother appears to still be in labor after that, a _____ should be called.
3. Problems delivering kittens are called _____. A _____ delivery is when the kitten arrives _____. A _____ is the surgical removal of the kittens through an _____ in the _____ and _____.
4. Post-natal problems can be _____, a depletion of _____, and _____, probably caused by a _____.
5. Newborn kittens should be watched for _____. Make sure they are getting enough to eat by rotating the weaker kittens to the _____ breasts where more milk is produced. If it is necessary to bottle feed a kitten, remember, a 2-3 day old kitten only takes in _____ drops of milk per feeding. The kitten will need to be fed every _____ hours.
6. Weaning will begin at _____ weeks and is usually completed by _____ weeks of age. At this time, a kitten should be taken to the _____ for a _____ and a _____.

SENSES

M L Z D A V I H Y V M R E K N
 U Y Q C E E E A R D R U M Z D
 D Z F H U U L Y O O M S O Q S
 I S F H S G J H T S D A U J S
 C X O A T N U F C N E H A H H
 U G N X A O E Y A O G W C S A
 L V V E C T M L F C C T D H D
 M S M P H H G M L I P U P C P
 U M Q I I T A U O U B L V N Y
 T P A D A E S C L E R A W S S
 E V R E N Y R O T I D U A C P
 P O W R I R I S D V T E P K A
 A S O M T P A P I L L A E K T
 T C G I E T L A V A Q M V O F
 I V E S R J C N L R F P H C K

Auditory nerve
 Cochlea
 Cornea
 Dermis
 Eardrum

Epidermis
 Eustachian
 Iris
 Lens
 Olfactory

Papillae
 Pupil
 Retina
 Sclera

Sweat glands
 Tapetum lucidum
 Taste buds
 Tongue

RESPIRATORY/CIRCULATORY

C G U E I Q N Y G M R Z D J U
 A G S P N H A J L G Y U C G R
 R W I T T L D R V J Z W R Y Z
 B D T H V V P H X N X D D V C
 O R T E P T W M O N N C G J R
 N P O L U R N T Y V E I N N U
 D L L N I A C R Q F D E U F D
 I A G A C C A E E H G D L V S
 O S I X T H P M O Y H J C P U
 X M P Q P E I A X G T K J Y S
 I A E D F A L O M B C U D E Y
 D O O L B S L E L L R J E Y N
 E S H K H E A R T E R Y R Y S
 Q M M Y E O R O G S S V Q Z N
 E P Y H P M Y L U J F J X Q A

Alveoli
 Artery
 Blood
 Bronchi
 Bronchioles

Capillary
 Carbon dioxide
 Epiglottis
 Heart
 Lung

Lymph
 Oxygen
 Pharynx
 Plasma

Platelets
 Spleen
 Trachea
 Vein

DIGESTIVE SYSTEM

S T O M A C H Z D D H O I V N
 A O G Z R M Y I X Y L G N H U
 L N J S U P F X R Y V L T D A
 I G W T S H W Z S D H D E U E
 V U C Y U R Q I I F K K S O T
 A E W X N Y R A H P R U T D L
 R E D D A L B L L A G N I E Z
 Y R A T N E M I L A E G N N R
 G B X N T E E T H I E Z E U V
 L A J E I M C P R S Y X G M I
 A U S R Q L O T T M P C O J V
 N L Z L I S U I E A G E C P C
 D R S V E N O S U R O L Y P T
 S A E R C N A P N E K I L I A
 T R K K K R B E K I F B G P X


Alimentary
 Anus
 Bile
 Diabetes
 Digest
 Digestion
 Duodenum

Enzymes
 Esophagus
 Gall bladder
 Gland
 Glycogen
 Insulin

Intestine
 Liver
 Nutrient
 Pancreas
 Pharynx
 Rectum

Saliva
 Salivary glands
 Stomach
 Teeth
 Tongue

CAT ANATOMY




Across

- 5. Regrow
- 6. Largest organ
- 7. Carry blood to heart
- 10. Stomach valve
- 11. Eye covering
- 13. Spinal column
- 14. Main artery
- 15. To close joint angle
- 16. Heat period

Down

- 1. Mating to birth
- 2. Neck vertebrae
- 3. Bronchi to alveoli
- 4. Inner layer of skin
- 8. Enrich with oxygen
- 9. Pharynx to lungs
- 12. Kidney to bladder

CAT ANATOMY 2




Across

- 3. Birthing problems
- 6. Connective tissue
- 7. Bile sack
- 11. Lower jaw
- 12. Involuntary muscle
- 14. Second vertebra


Down

- 1. Mouth to stomach
- 2. Fluid made by liver
- 4. Voluntary muscle
- 5. Air-filled pocket
- 8. Union of two bones
- 9. Knee cap
- 10. Blood fluid
- 13. Body that forms eggs


FELINE EVOLUTION (from Page 8)




SENSES (from Page 36)



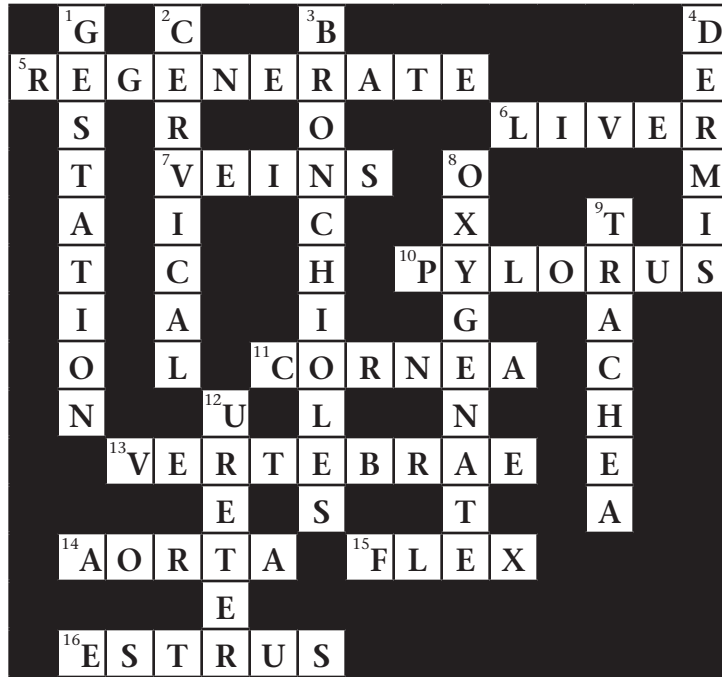
RESPIRATORY/CIRCULATORY (from Page 37)



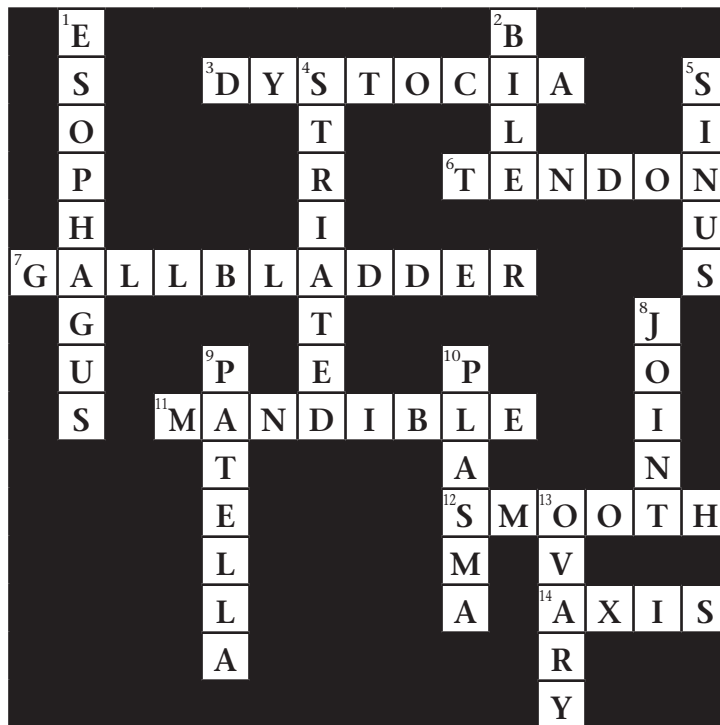
DIGESTIVE SYSTEM (from Page 38)



CAT ANATOMY (from Page 39)



CAT ANATOMY 2 (from Page 40)



WASHINGTON STATE UNIVERSITY
 EXTENSION

4-H Youth Development Program 

Issued by Washington State University Extension and the U.S. Department of Agriculture in furtherance of the Acts of May 8 and June 30, 1914. Extension programs and policies are consistent with federal and state laws and regulations on nondiscrimination regarding race, sex, religion, age, color, creed, and national or ethnic origin; physical, mental, or sensory disability; marital status or sexual orientation; and status as a Vietnam-era or disabled veteran. Evidence of noncompliance may be reported through your local WSU Extension office. Trade names have been used to simplify information; no endorsement is intended. Revised August 2013.

EM4289E